

ARTICLE

Mucoid enteropathy/epizootic rabbit enteropathy in two species of cottontail rabbits: four recent cases

Gabriele C. Paul & Daniel G. Friend

Colorado Wild Rabbit Foundation, Erie, CO, USA

Abstract

Mucoid enteropathy/epizootic rabbit enteropathy is a disease of domestic European rabbits (*Oryctolagus cuniculus*) that has been recognized for nearly 50 years but is still not well understood. Morbidity and mortality are high and can lead to large losses in domestic rabbit production facilities. Recently, the Colorado Wild Rabbit Foundation identified four cases with similar presentations in two species of cottontail rabbits (*Sylvilagus* spp.) undergoing rehabilitation (2020–2022). Clinical signs, gross pathology, and histopathology findings were consistent with what has been described in domestic rabbits.

BIO

Gabriele C. Paul has been involved in wildlife rehabilitation since 2007, and has focused exclusively on lagomorph rehabilitation since 2013. She is the co-founder and Director of the Colorado Wild Rabbit Foundation. Gabriele has a master's degree in biology from the University of Colorado and is a Certified Wildlife Rehabilitator (CWR). She is licensed by the state of Colorado for the rehabilitation of small mammals.

Daniel G. Friend has been involved in lagomorph rehabilitation since 2010, and was a founding Director of the Colorado Wild Rabbit Foundation in 2013, in which he maintains an active role. He recently retired as a research physicist (Cornell University, AB and University of Colorado, PhD) and continues active leadership roles in several domestic and international physics-focused organizations.

Introduction

Mucoid enteropathy/epizootic rabbit enteropathy (ME/ERE) is an important disease of domestic European rabbits (*Oryctolagus cuniculus*) that has been recognized for nearly 50 years but is still not well understood, and the etiology is unknown (Puón-Peláez et al. 2018). Characteristic features include cecal impaction and large amounts of gelatinous mucus in the colon, and often gastric dilation (Barthold et al. 2016; Varga Smith 2023). A defining feature is the absence of inflammatory or congestive lesions in the gastrointestinal tract (Hu et al. 2018). Morbidity and mortality are high, often leading to large losses in domestic rabbit production facilities. However, while some treatments and prevention strategies have been proposed (Puón-Peláez et al. 2018), there is some uncertainty as to their effectiveness (Varga Smith 2023). This report describes findings consistent with ME/ERE in four cottontail rabbits undergoing rehabilitation at the CWRF.

Keywords

Captive rearing; emerging disease surveillance; rabbit diseases; wildlife rehabilitation

Correspondence

Gabriele C. Paul, Colorado Wild Rabbit Foundation, PO Box 1253, Erie, CO 80516, USA. E-mail: cowildrabbit@yahoo.com

Abbreviations

CWRF: Colorado Wild Rabbit Foundation
ERE: epizootic rabbit enteropathy
ME: mucoid enteropathy
PCR: polymerase chain reaction

Dates

Received: 7 January 2023
Accepted: 1 August 2023
Published: 31 August 2023

Background and case reports

While mucoid enteropathy has been described in domestic European rabbits since at least 1974 (Flatt et al. 1974), more recently, a highly infectious component to this disease was discovered in domestic rabbit breeding facilities; the disease is now called epizootic rabbit enteropathy (Puón-Peláez et al. 2018). ERE first emerged in Europe in 1996 and was reported in Mexico in 2001/2002 (Puón-Peláez et al. 2018). Rabbits inoculated with the cecal contents from infected rabbits developed the disease, and large outbreaks with high morbidity and mortality have been reported (Licois et al. 2005). The infectious agent has not yet been identified, although several candidates have been proposed (Puón-Peláez et al. 2018; Puón-Peláez et al. 2020). The disease is thought to be bacterial in nature, and current practices in large breeding facilities seem to now be able to control the disease through strict hygiene and the administration of antibiotics such as valnemulin, tiamulin (Dip et al.

2015) and bacitracin (Maertens et al. 2010). Barthold et al. (2016) distinguish between the two diseases, with mucoid enteropathy described as a non-infectious disorder and ERE as an infectious disease thought to be caused by *Clostridium perfringens*. Hu et al. (2018), investigating the emergence and rapid spread of an ERE-like disease (“mucoid enteropathy syndrome”) in China, found the cecal microbiome of affected rabbits in China differed from that reported in ERE rabbits in Europe, possibly indicating a different causative agent. However, ERE is now considered to be the same disease as mucoid enteropathy (Puón-Peláez et al. 2018; Varga Smith 2023).

ME/ERE mostly occurs in young, recently weaned rabbits, although adults can sometimes be affected (Puón-Peláez et al. 2018; Varga Smith 2023). Clinical signs described by these authors include a distended abdomen, reduced appetite often leading to anorexia, and mild diarrhea followed by reduced or complete cessation of fecal production. They indicate that death usually follows one to nine days after the onset of clinical signs. According to Varga Smith (2023), these clinical signs can also be caused by other diseases such as hepatic coccidiosis and enteritis (which can have various causes in young rabbits). However, the diagnosis of ME/ERE can be confirmed when necropsy reveals large amounts of mucus, primarily in the colon (but sometimes also in the cecum and small intestines), and the absence of other lesions (Barthold et al. 2016; Varga Smith 2023). Barthold et al. (2016) describe the cecum as often impacted, the small intestines and sometimes the stomach as distended with ingesta and gas, and a large production of mucin from the goblet cells in the small and large intestines. Histopathologically, no inflammatory lesions are evident, which distinguishes ME/ERE from other enteropathies

(Puón-Peláez et al. 2018). The above describes ME/ERE in domestic European rabbits. However, pathologies associated with mucoid enteritis in captive cottontail rabbits were described in a report by Richter and Hendren (1969); these are inconsistent with ME/ERE as described in domestic rabbits by Barthold et al. (2016). Richter and Hendren reported inflammation and other lesions, which are not features of ME/ERE.

The four cases at CWRF with similar presentation as ME/ERE were identified post-mortem: three in 2020 (two eastern cottontail rabbits, *Sylvilagus floridanus* and one desert cottontail rabbit, *S. audubonii*); and one in 2022, an eastern cottontail rabbit. All four cases occurred in recently weaned rabbits, ranging in age from approximately four to eight weeks and with body weights between 170 and 200 g at time of death. Their circumstances for admission varied: one was attacked by a cat, two became trapped in window wells and sustained injuries, and one was orphaned. Clinical signs, as well as gross and histopathologic findings in these four individuals were very similar to those described for ME/ERE in domestic rabbits by Barthold et al. (2016). The clinical signs observed included a distended abdomen with cecal bloat or impaction; piloerection and a hunched posture, indicating abdominal pain; weight plateau or slight loss; reduced appetite or anorexia; and reduced fecal production, sometimes accompanied by mucus. Two rabbits had mild diarrhea early at the onset of clinical signs. All four rabbits died or were euthanized within five to 10 days after first signs appeared.

Gross necropsy findings included a severely distended and impacted cecum; small intestines distended with ingesta; and a large amount of mucus in the large intestines, primarily in the proximal colon (Fig. 1). One

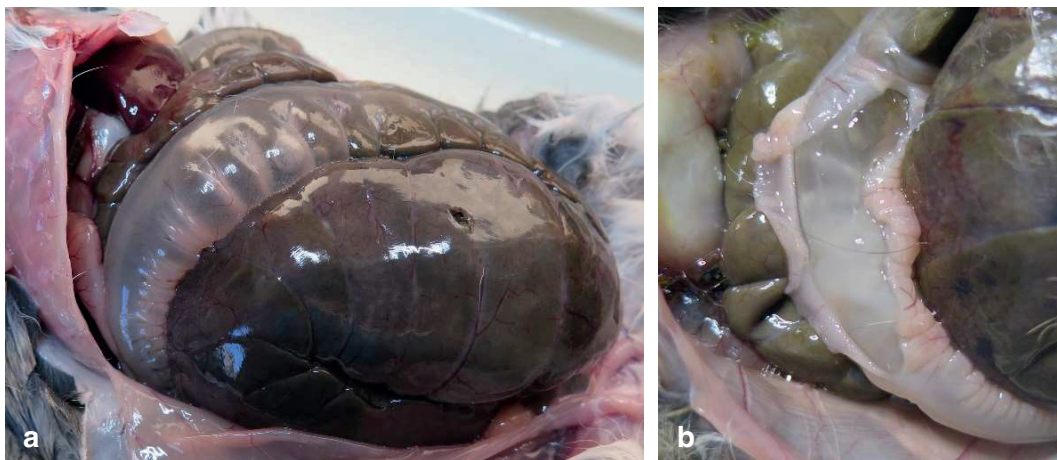


Fig. 1 Necropsies of young cottontail rabbits with presumed mucoid enteropathy/epizootic rabbit enteropathy showing an impacted cecum and large amounts of mucus in the proximal colon.

rabbit also had gastric dilatation. No other gross lesions were observed in any of the four rabbits. PCR testing of feces from two rabbits for *C. perfringens* and *E. coli*, mentioned by Barthold et al. (2016) as possible contributing agents to ME/ERE in domestic rabbits, were negative. For the three cases presenting in 2020, a presumptive diagnosis of ME/ERE was made at CWRP based on the gross necropsy findings described above. (Due to resource constraints, CWRP does not routinely submit samples for further testing unless unexplained lesions are found.) When an additional case was diagnosed at CWRP two years later, the authors more thoroughly reviewed the literature. To the authors' knowledge, no cases of ME/ERE in cottontail rabbits had been documented; it thus became clear that it was important to conduct additional testing and to alert the wildlife rehabilitation community to the possible emergence of a new disease and potentially increase surveillance. Therefore, the authors took the additional step of confirming the absence of lesions by submitting tissue samples for histopathology. No evidence of inflammation or infectious organisms was found in any of the tissues examined (heart, lung, liver, kidney, small intestines, cecum, colon). According to the histopathology report, "the underlying cause of death is not apparent in the examined tissue sections. There is no histologic evidence of inflammation or infectious organisms in the remaining examined tissues."

Discussion

Factors thought to contribute to the development of ME/ERE in domestic rabbits include diet, with insufficient insoluble fiber related to increased cases, stress, a variety of infectious agents, and coinfections with common rabbit pathogens such as coccidia, *Clostridium* spp., or *E. coli* (Barthold et al. 2016; Puón-Peláez et al. 2020; Varga Smith 2023). Patients at CWRP were fed a diet consisting mostly of fresh grass, supplemented with small amounts of alfalfa hay and forbs. This mimics the natural diet of cottontail rabbits (Armstrong et al. 2011), and the authors therefore don't suspect diet as a primary cause. Stress is certainly an issue in captive wild cottontail rabbits (Tseng 2020) and could have been a contributing factor. However, there was no indication that these particular rabbits were under increased stress as compared to the other rabbits in our care at the same time. Their circumstances of admission (window well entrapment, orphaning, cat attack) are common reasons for intake, and their injuries were not particularly severe. Coccidiosis is a major disease in young cottontail rabbits (Paul & Friend 2019): while all patients at CWRP are prophylactically treated

for coccidiosis, breakthrough infections do occasionally occur (Paul & Friend 2021). All four cases discussed here showed signs of GI disease (as described above) prior to death. However, no gross lesions associated with coccidiosis or any other gastrointestinal diseases were observed at necropsy. Our protocols include fecal exams on all patients that exhibit signs of GI disease; in these four cases, no coccidia oocysts or other parasites were found. One rabbit died and three were euthanized due to the severity of their clinical signs. In all cases, coccidiosis was the top differential, but no improvement was seen despite treatment for this disease. (See Paul & Friend 2021 for a description of the protocol used at CWRP for prevention and treatment of coccidiosis.) No clinical signs specific to ME/ERE were observed in any of these cases.

While ME/ERE has been described as a highly contagious disease in domestic rabbit breeding facilities, with large outbreaks reported (Puón-Peláez et al. 2018), there was no apparent transmission within CWRP. While the authors saw no evidence of an infectious agent, factors such as diet, husbandry practices, and species-specific infectivity may have prevented an outbreak at CWRP. Whether this disease has the potential to become epizootic in wild or captive cottontail rabbit populations is unknown.

Conclusion

ME/ERE appears to be a rare disease in cottontail rabbits, with only four cases presumptively diagnosed out of 1,075 cottontail patients received at CWRP during the three-year period from 2020 to 2022. These cases occurred in rabbits that had been in rehabilitation for at least one week before the onset of clinical signs; the question remains whether this disease results from factors related to captivity or also occurs naturally in the wild. To our knowledge, neither mucoïd enteropathy nor ERE has been previously reported in cottontail rabbits. Wildlife veterinarians and rehabilitators are in a unique position to monitor for and detect new or emerging diseases in wildlife. Whether the findings presented in this article constitute a possible emerging disease or spillover from domestic rabbits is not known; however, wildlife experts working with cottontail rabbits should be alert to the possibility of any new threat to native lagomorph species.

Acknowledgements

The authors thank all of those who rescue wild animals experiencing crisis and our colleagues in the rehabilitation community who care for them.

Disclosure statement

The authors report no conflict of interest.

Funding

The authors received no specific funding for this study.

References

- Armstrong D.M., Fitzgerald J.P. & Meaney C.A. 2011. Genus *Sylvilagus* – American rabbits. In D.M. Armstrong et al. (eds.): *Mammals of Colorado*. 2nd ed. Pp. 264–270. Boulder, CO: University Press of Colorado.
- Barthold S.W., Griffey S.M. & Percy D.H. 2016. Rabbit. In S.W. Barthold et al. (eds.): *Pathology of laboratory rodents and rabbits*. 4th ed. Pp. 273–275. Ames, Iowa: Wiley-Blackwell. doi: 10.1002/9781118924051.ch06.
- Dip R., Nemet Z., Schiessl B., Klein U. & Strehlau G. 2015. Efficacy and tolerability of early administration of valnemulin hydrochloride premix on epizootic rabbit enteropathy. *The Veterinary Journal* 204(3), 309–314. doi: 10.1016/j.tvjl.2014.12.036.
- Flatt R.E., Weisbroth S.H. & Kraus A.L. 1974. Mucoid enteropathy. In Chapter 17: metabolic, traumatic, mycotic, and miscellaneous diseases of rabbits. In *The biology of the laboratory rabbit*. 1st ed. Pp. 437–440. New York, NY: Academic Press. doi: 10.1016/C2013-0-11681-9.
- Hu B., Fan Z., Wei H., Song Y., Qiu R., Chen M., Xu W., Xue J. & Wang F. 2018. Detection of mucoid enteropathy syndrome disease in rabbit farms in East China. *Research in Veterinary Science* 119, 259–261. doi: 10.1016/j.rvsc.2018.07.011.
- Licois D., Wyers M. & Coudert P. 2005. Epizootic rabbit enteropathy: experimental transmission and clinical characterization. *Veterinary Research* 36, 601–613. doi: 10.1051/vetres:2005021.
- Maertens L., Cornez B., Vereecken M. & Oye S. 2010. Efficacy study of soluble bacitracin (Bacivet S(R)) in a chronically infected epizootic rabbit enteropathy environment. *World Rabbit Science* 13(3), 165–178. doi: 10.4995/wrs.2005.520.
- Paul G.C. & Friend D.G. 2019. Clostridial Enterotoxemia and coccidiosis in weanling cottontail rabbits (*Sylvilagus audubonii*, *Sylvilagus floridanus*, *Sylvilagus nuttallii*) from Colorado, USA. *Journal of Wildlife Diseases* 55, 189–195. doi: 10.7589/2018-02-026.
- Paul G.C. & Friend D.G. 2021. Aggressive treatment of young cottontail rabbits (*Sylvilagus* spp.) for coccidiosis resulted in large reduction in gastrointestinal disease mortality from all causes (Colorado, USA). *Journal of Wildlife Rehabilitation* 41, 7–12.
- Puón-Peláez X.-H.D., McEwan N.R., Gómez-Soto J.G., Álvarez-Martínez R.C. & Olvera-Ramírez A.M. 2020. Metataxonomic and histopathological study of rabbit epizootic enteropathy in Mexico. *Animals (Basel)* 10, 936–950. doi: 10.3390/ani10060936.
- Puón-Peláez X.-H.D., McEwan N.R. & Olvera-Ramírez A.M. 2018. Epizootic Rabbit Enteropathy (ERE): a review of current knowledge. *European Scientific Journal* 14, 137–149. doi: 10.19044/esj.2018.v14n36p137.
- Richter C.B. & Hendren R.L. 1969. The pathology and epidemiology of acute enteritis in captive cottontail rabbits (*Sylvilagus floridanus*). *Veterinary Pathology* 6, 159–175. doi: 10.1177/030098586900600206.
- Tseng F.S. 2020. Natural history and medical management of lagomorphs. In S.M. Hernandez et al. (eds.): *Medical management of wildlife species*. Pp. 185–195. Hoboken, NJ: John Wiley & Sons, Inc. doi: 10.1002/9781119036708.ch15.
- Varga Smith M. 2023. Epizootic rabbit enteropathy. In *Chapter 5: Digestive disorders. Textbook of rabbit medicine*. 3rd ed. Pp. 177–179. Edinburgh, United Kingdom: Elsevier.